

Management of Oesophageal Perforation after Delayed Diagnosis : the Merit of Tissue Flap Reinforcement

A. Rosiere, S. Mulier, A. Khoury, L. A. Michel

Surgical services, Université Catholique de Louvain at Mont-Godinne University Hospital, 5530 Yvoir, Belgium.

Key words. Oesophageal perforation ; Boerhaave's syndrome, tissue flap reinforcement, endoscopy.

Abstract. Oesophageal perforation remains a life-threatening situation and its management represents a challenge for the surgeon, especially if diagnosis has been delayed. In most cases, a surgical approach is indicated. Simple primary repair often result in leakage. In order to avoid leakage, the primary repair should be buttressed with some kind of tissue flap. We here report our experience with 15 esophageal perforations and 10 tissue flap reinforcements performed during the last decade. The different types of tissue flap are illustrated and their results are compared with more aggressive alternatives such as oesophagectomy, T-tube drainage and oesophageal exclusion.

Introduction

Oesophageal perforations continue to carry a severe prognosis especially if diagnosis has been delayed. In these cases, the morbidity and mortality rate are respectively close to 50% and 20% (1). Simple primary suture of the perforation is frequently complicated by leakage and surgeons are forced to proceed to other surgical techniques like tissue flap reinforcement, esophageal drainage or exclusion and sometimes even to oesophagectomy. We here described our experience with tissue flap reinforcement of the suture site.

Material and methods

During the last decade, we have been faced with 15 such patients (age range : 18-72 year), eight men and seven women. Seven patients were referred from another institution. The perforation was localised in the cervical oesophagus in three cases, in the thoracic oesophagus in eight cases and in the abdominal portion in four cases. The cause of perforation was upper GI endoscopy in five cases (four associated to oesophageal varices sclerotherapy and one after rigid endoscopy) ; surgical procedure in five cases (two coelioscopic funduplications, one total thyroidectomy for a thyroid myeloma extending to the cervical oesophagus, one Zenker's diverticulum treated by laser and one total gastrectomy) ; spontaneous post-emetic perforation (Boerhaave's syndrome) in three cases ; cervical trauma (gunshot wound) in one case and foreign body (chicken bone) in one case.

Results

The diagnosis was suspected on the basis of clinical signs (pain, dyspnea, subcutaneous emphysema) in 11 patients and confirmed by water-soluble contrast oesophagogram in 10 patients. In one patient, the oesophagogram did not demonstrate the perforation. In addition, for thoracic perforation a computed tomography (CT) scan was performed in six patients and showed a pneumomediastinum with pleural effusion in three patients and empyema in the three others. Oesophageal perforation was also diagnosed during selective devascularisation of the upper stomach and lower esophagus (i.e., Sugiura's procedure) in four patients with active variceal bleeding despite several unsuccessful attempts of endoscopic sclerotherapy. None of these four patients had oesophageal contrast study before operation.

Prompt diagnosis was made in only three patients less than eight hours after the perforation. In six patients, the diagnosis was made after more than 12 hours and in six more than 24 hours.

Three patients were treated non operatively (one patient with foreign body, one after thyroidectomy for thyroid myeloma and one after total gastrectomy) and the 12 others were operated as soon the diagnosis was made. After localisation of the site of perforation and extensive lavage, the oesophagus was exposed for primary repair of the perforation. At this time, a nasogastric tube was positioned under digital control. Intra operative exposition of the muscular and mucosal injury followed by complete debridement of necrotic oesophageal tissues were performed in all operated cases. The perforation was then closed in two layers of interrupted sutures.

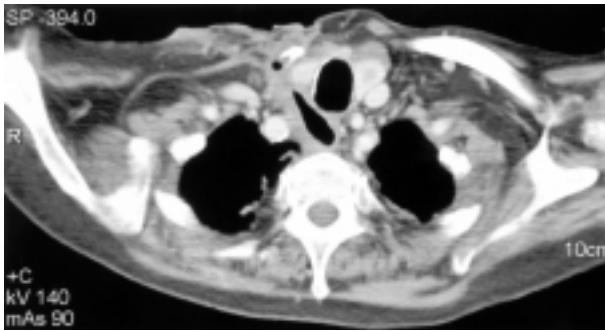


Fig. 1

Post-operative CT scan showing the defect of the right lateral wall of the cervical oesophagus (Zenker diverticulum laser resection).

Primary suture of the perforation was performed in 11 patients associated in 10 by reinforcement of the suture line with a tissue flap. In another patient, simple drainage was performed because we could no find the perforation. The tissue flap reinforcement consisted in gastric wall six times, epiploasty twice, a pleural wrap once and a pectoralis major myocutaneous flap once.

The overall morbidity rate was 20% with, however, no complication for the three patients treated non operatively. Three complications occurred in the operative group. Two patients presented post operative leakage. The first had cervical perforation after ENT treatment by laser of a Zenker's diverticulum. Initial primary suture without reinforcement was performed in another institution. A leakage occurred on the second postoperative day which was treated only by drainage. A massive haemorrhage from septic erosion of the right internal carotid artery occurred one week later which was controlled by emergency ligation of the internal carotid without any cerebral consequence fortunately enough. After referral of the patient, CT of the cervical region was performed showing (Fig. 1) extensive destruction of the right lateral wall of the cervical oesophagus. As it was impossible to perform a primary repair with reinforcement, oesophageal exclusion had to be performed with stapling of the gastro-oesophageal junction, plus gastrostomy for prolonged drainage and jejunostomy for enteral feeding. Due to the extensive destruction of the cervical oesophagus, cervical oesophagostomy was found impossible to perform and an adequate drainage of the neck area was realised. This patient was planned for oesophageal replacement as soon as he would have recovered a satisfactory condition. Nevertheless, so far this patient has not yet been re-operated because progressive epithelial replacement at the level of the cervical oesophagus channel is spontaneously occurring.

The second patient presenting with post operative leakage sustained a gunshot wound in the neck. The projectile crushed the left lobe of the thyroid and the cervi-

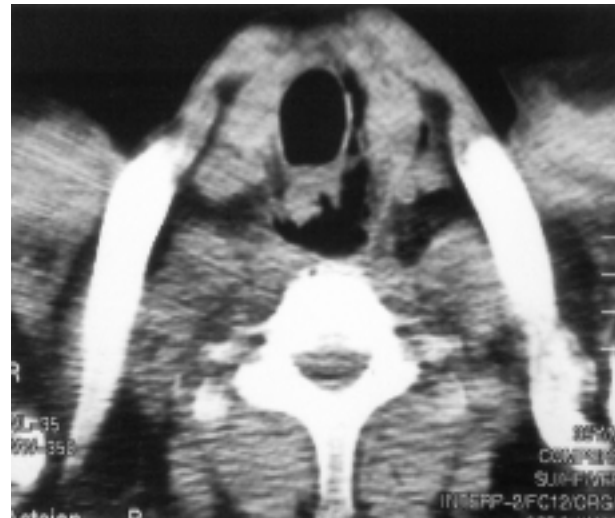

Fig. 2

Pre-operative CT scan showing the course of the bullet having destroyed the left thyroid lobe and the cervical oesophagus.

cal oesophagus (Fig. 2), while sparing the neck vessels and the trachea. We realised the replacement of the widely destroyed cervical oesophagus by a pectoralis major myocutaneous flap. A leakage occurred on the fourth postoperative day and we had to perform gastrostomy for drainage and jejunostomy for feeding. Oesophageal exclusion was not necessary because the fistula flow was low and finally closed.

A third patient developed a right empyema six days after primary repair of the lower thoracic oesophagus reinforced by a gastric wall flap. A water soluble contrast oesophagogram showed no leakage and we realised drainage of the right pleural space with no further complication.

The overall mortality rate was 13% (2/15): one patient died of acute hepatic failure and another young patient developed an acute leukaemia. The site of oesophageal perforation was healed and sealed at the time their death occurred.

Discussion

The frequency of leakage after primary suture has been estimated to be between 36 and 50% (2). It represents the main challenge for the surgeon because of the contamination of the surrounding tissues and cavities, the poor vascularisation of the oesophagus and the lack of a serous layer. Furthermore, the mucosal tear is frequently longer than the muscular defect. Few authors (3, 4) insist on the necessity to realise a debridement of necrotic tissues as well as the eventual enlargement of the muscular laceration in order to clearly expose the mucosal defect before performing complete closure in two layers of interrupted suture.

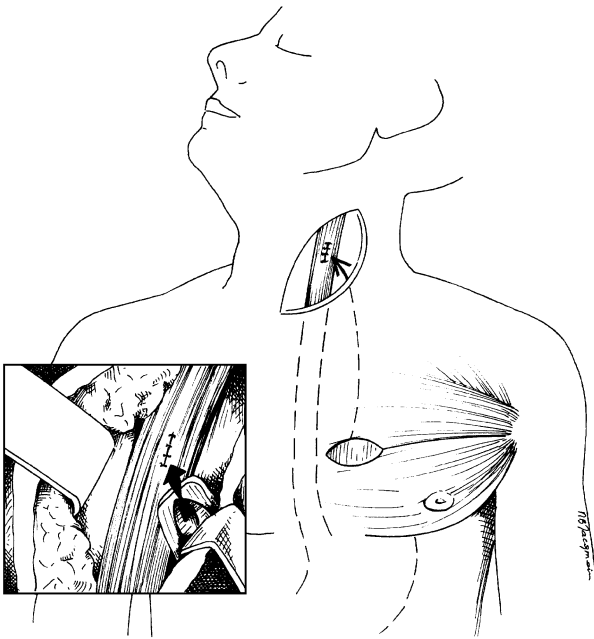


Fig. 3

Pectoralis major myocutaneous flap tunneled into the cervical field and inverted in order to suture the skin paddle on the oesophageal repair with the well vascularised muscle above.

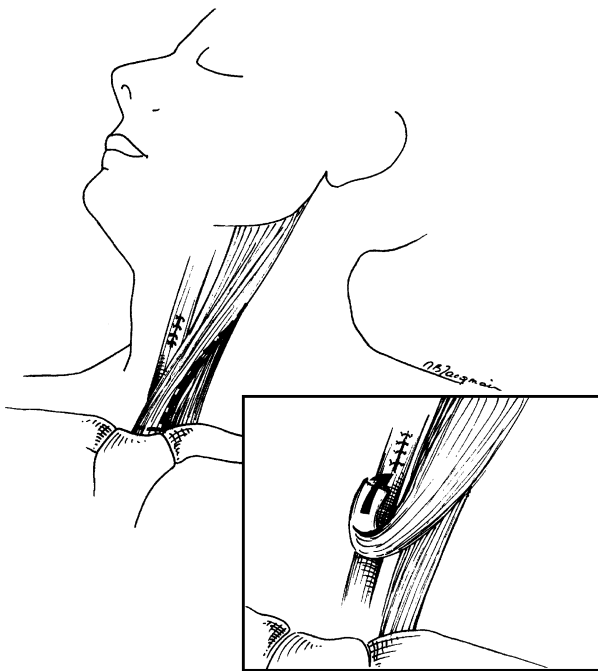


Fig. 4

Sternocleidomastoid muscle flap : the sternal head of the muscle is detached from its lower origin, divided in its lower two thirds and transposed over the oesophageal repair.

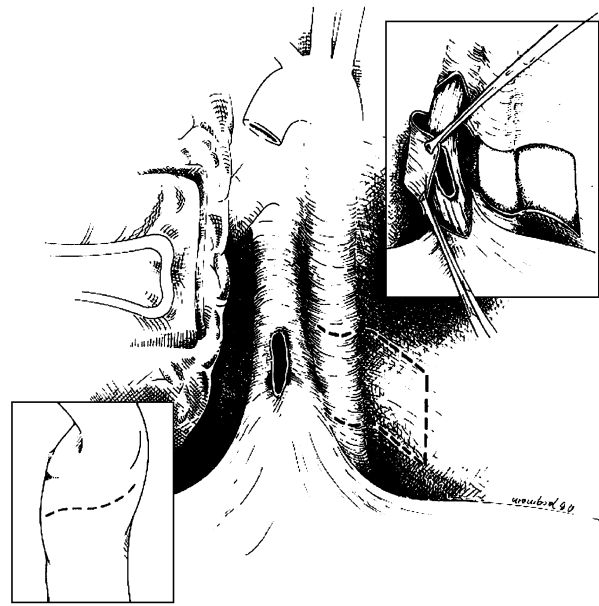


Fig. 5

Grillo pleural flap : the thickened pleura is mobilised and transposed around the perforation or eventually around the oesophagus.

Reinforcement of the suture line by a local tissue flap reduces the incidence of leakage (10% in our series) (2, 5). This is the reason why we buttress all suture repairs with some kind of autogenous tissue.

For cervical oesophagus perforation, the best flap is probably the pectoralis major myocutaneous flap (Fig. 3) because of its mobility, its skin paddle for epithelial replacement and its well-vascularised muscular tissue (6, 7). The sternocleidomastoid muscle flap (Fig. 4) is also proposed (8), but its necrosis rate is close to 50% and is most likely related to a more unpredictable and random blood supply (7).

For thoracic perforation, all tissues that can be easily mobilised in order to cover the oesophageal suture line have been described. The most popular flap is the Grillo pleural flap (Fig. 5) because it is rather easy to make especially after delayed diagnosis when the pleura has become thickened by the inflammatory process. (2, 9). The second most widely used flap is the Thal flap made out the stomach wall (Fig. 6) (10). When used to reinforce the suture line of a thoracic perforation, it only requires a small phrenotomy with low risk to contaminate the abdominal cavity. The omentum represents another alternative in case of prior gastric surgery (11). Furthermore, it can fill in an infected pleural space. Its disadvantage is the necessity to perform a laparotomy to mobilise the omental flap on the right gastroepiploic artery. We realised this flap for two patients : the first had a gastropexy performed six months before for gastric volvulus and the second had a laparoscopic antireflux

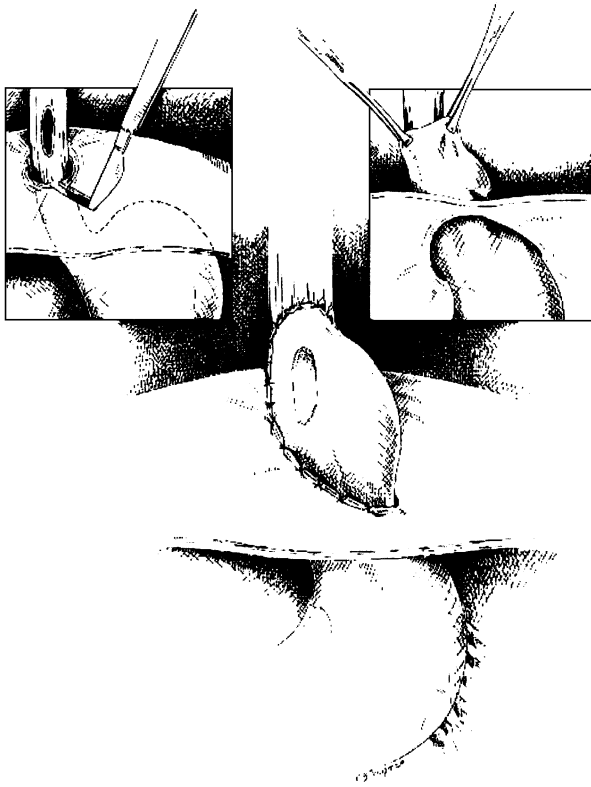


Fig. 6

Thal flap : through a small phrenotomy, the stomach fundus is drawn up into the thorax after ligation of the short gastric vessels.

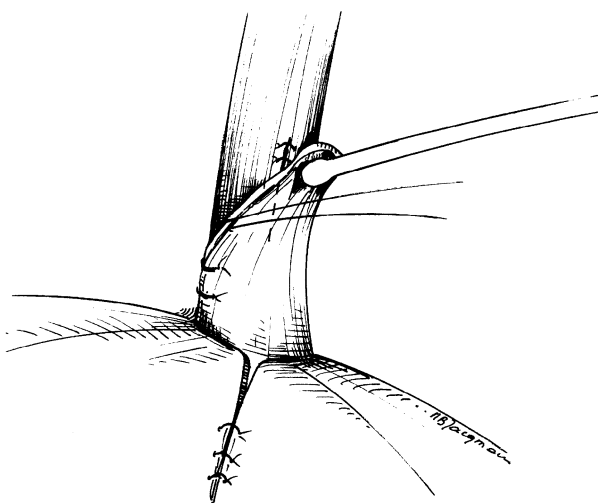


Fig. 7

Flap from the diaphragm : the flap is prepared by cutting the diaphragm in a U shape fashion and rotated to cover the oesophageal suture repair.

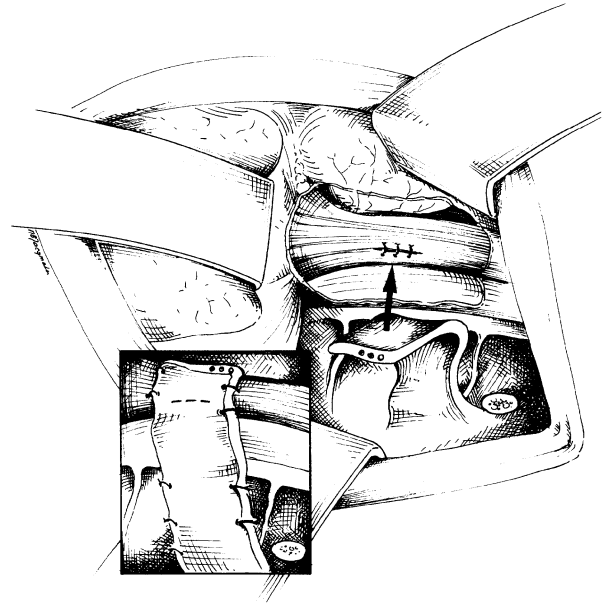


Fig. 8

Intercostal pedicle flap : the flap must be prepared before inserting the rib retractor to avoid crushing the neurovascular intercostal bundle.

fundoplication performed ten days before with ascension of the fundoplication into the thorax.

Muscle flaps have also been recommended because they are thick and supposedly more resistant to necrosis. The first type is the flap made out of diaphragm (Fig. 7) described by Rao (12) but caution should be taken not to injure the spleen or the liver. The second type of muscle flap is the intercostal muscle flap (Fig. 8) described by Richardson (13). This flap requires mobilisation before opening the chest in order to avoid crushing its neurovascular bundle by the rib retractor.

For abdominal perforation, the best flap is a 360° fundoplication around the oesophageal suture repair line. We performed this flap four times with no leakage (14).

In the management of delayed perforation, some authors reported their experience with oesophagectomy (15, 16) but the result is not superior to primary repair with tissue flap reinforcement. The mortality rate varies from 13 to 66% and the morbidity rate is close to 50% (2). Oesophageal resection should be kept as a treatment option for perforation associated with intrinsic underlying oesophageal disease (i.e., cancer).

Other surgical procedures as T-tube drainage (17, 18) and oesophageal exclusion (19, 20) have been recommended in patients with failure of primary repair or with very poor general condition, but the mortality rate is high (35 to 50%) (1). In our current experience, we had to resort to complete oesophageal exclusion in the

patient who sustained cervical perforation after ENT laser surgery for a Zenker's diverticulum.

Conclusion

Our experience suggests that to reinforce and to buttress all suture repairs of oesophageal perforation with a tissue flap is the best way to avoid persisting leakage. Although the concept is simple for such dramatic situations, many surgeons do not apply it systematically. Several kinds of tissue flaps can be used and it is usually possible to perform one of them without significant operative difficulty.

References

- GIUDICELLI R. Les perforations de l'œsophage. Résultats d'une enquête nationale. *Ann Chir Thorac Cardio-Vasc*, 1992, **46** : 183-187.
- GOUGE T. H., DEPAN H. J., SPENCER F. C. Experience with the Grillo pleural wrap procedure in 18 patients with perforation of the thoracic oesophagus. *Ann Surg*, 1989, **209** : 612-617.
- WHYTE R. I., IANNETTONI M. D., ORRINGER M. B. Intrathoracic esophageal perforation. The merit of primary repair. *J Thorac Cardiovasc Surg*, 1995, **109** : 140-146.
- FRIEDBERG J. S., DEEB M. E. Esophageal perforation. In : BAKER J. R., FISHER J. E. (eds.). *Master of Surgery*. Philadelphia : Lippincott Williams and Wilkins, 2001, vol 1 : 843-852.
- MICHEL L., GRILLO H. C., MALT R. A. Esophageal perforation. *Ann Thorac Surg*, 1982, **33** : 203-210.
- CUSUMANA R. T., SILVER C. E., BRANER R. J. Pectoralis myocutaneous flap for reconstruction of cervical esophagus. *Head Neck*, 1989, **11** : 450-456.
- HEITMILLER R. F., MCQUONE S. J., EISELE D. W. The utility of the pectoralis myocutaneous flap in the management of selected cervical esophageal anastomotic complications. *J Thorac Cardiovasc Surg*, 1998, **115** : 1250-1254.
- BARLOW C. W., SCHEIN M. Primary sternocleidomastoid muscle flap in emergency reconstruction of traumatic oesophageal defect. Case report. *Eur J Surg*, 1991, **157** : 419-420.
- GRILLO H. C., WILKINS E. W. Esophageal repair following late diagnosis of intrathoracic perforation. *Ann Thorac Surg*, 1975, **20** : 387-399.
- THAL A. P., HATAFUKU T. Improved operation for esophageal rupture. *JAMA*, 1964, **188** : 826-828.
- MATHISEN D. J., GRILLO H. C., VLAHAKES G. J., DAGGET W. M. The omentum in the management of complicated cardiothoracic problems. *J Thorac Cardiovasc Surg*, 1988, **95** : 677-684.
- RAO K. V. S., MIR M., COGBILL C. L. Management of perforations of the thoracic esophagus : a new technique utilizing a pedicle flap from the diaphragm. *Am J Surg*, 1974, **127** : 609-612.
- RICHARDSON J. D., MARTIN L. F., BORZOTTA A. P., POLK H. C. Unifying concepts in treatment of esophageal leaks. *Am J Surg*, 1985, **149** : 157-162.
- ROSIERE A., MICHEL L., DE CANNIERE L., VANDENBOSSCHE P., JOUCKEN K. Surgery as a "last resort option" for active variceal bleeding further complicated by iatrogenic oesophageal perforation. *Br J Surg*, 1994, **81** : 863-865.
- MATTHEWS H. R., MITCHELL I. M., MCGUIGAN J. A. Emergency subtotal oesophagectomy. *Br J Surg*, 1989, **76** : 918-920.
- SALO J. A., ISOLAURI J. O., HEIKKILÄ L. J., MARKKULA H. T., HEIKKINEN L. O., KIVILAAKSO E. O. *et al.* Management of delayed esophageal perforation with mediastinal sepsis. Esophagectomy or primary repair ? *J Thorac Cardiovasc Surg*, 1993, **106** : 1088-1091.
- ABBOTT O. A., MANSOUR K. A., LOGAN W. D., HATCHER C. R. M., SYMBAS P. N. Atraumatic so-called "spontaneous" rupture of the esophagus. *J Thorac Cardiovasc Surg*, 1970, **59** : 67-83.
- NAYLOR A. R., WALKER W. S., DARK J., CAMERON E. W. J. T-tube intubation in the management of seriously ill patients with esophagopleural fistulae. *Br J Surg*, 1990, **77** : 40-42.
- URSHEL H. C., RAZZUKK M. A., WOOD R. E., GALBRAINTH N., POCKEY M., PAULSON D. L. Improved management of esophageal perforation : exclusion and diversion in continuity. *Ann Surg*, 1974, **179** : 587-591.
- VIDREQUIN A., MANGIN P., BECK M., BRESLER L., BOISSEL P., GROSIDIER J. Exclusion œsophagienne par agrafes résorbables : application au traitement conservateur en un temps du syndrome de Boerhaave. *Ann Chir*, 1988, **42** : 267-270.

A. Rosiere
Surgical Service
Mont-Godinne University Hospital
B-5530 Yvoir, Belgium
Tel. : 081/423051
E-mail : alain.rosiere@chex.ucl.ac.be